

Nardocci N. Iron - related MRI images in patients with pantothenate kinase - associated neurodegeneration (PKAN) treated with deferiprone: results of a phase II pilot trial. *Mov Disord*, 2011, 26:1756-1759.

[22] Kurian MA, McNeill A, Lin JP, Maher ER. Childhood disorders of neurodegeneration with brain iron accumulation (NBIA). *Dev Med Child Neurol*, 2011, 53:394-404.

(收稿日期:2013-11-05)

· 临床医学图像 ·

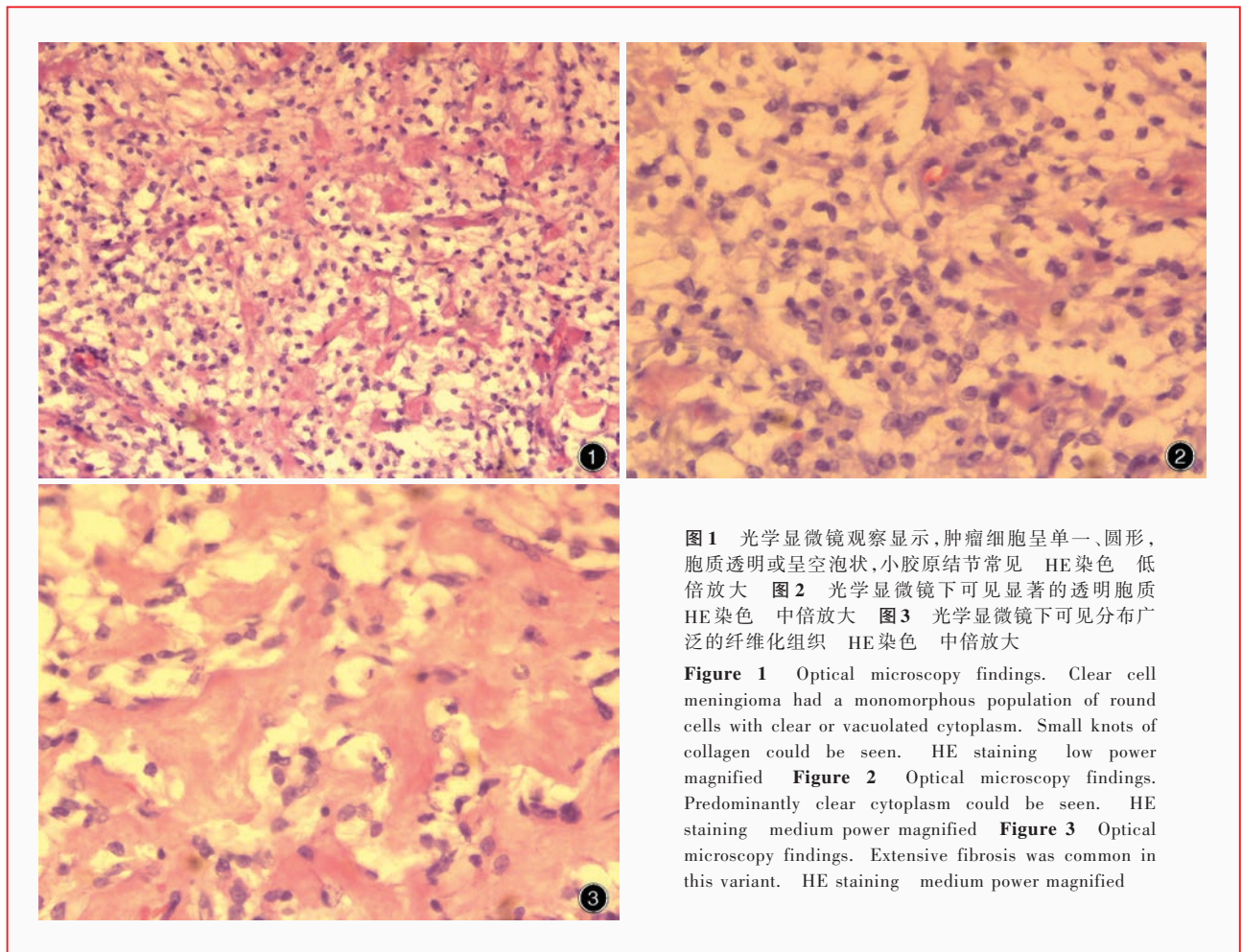
透明细胞型脑膜瘤

doi: 10.3969/j.issn.1672-6731.2014.02.014

Clear cell meningioma

YAN Xiao-ling

Department of Pathology, Tianjin Huanhu Hospital, Tianjin 300060, China (Email: ll934065@126.com)



透明细胞型脑膜瘤好发于脊髓和颅后窝,是临床少见的脑膜瘤亚型。肿瘤组织由多角形、胞质透明、富含糖原的肿瘤细胞组成,血管周围和间质胶原纤维丰富(图1,2);“旋涡”状结构常呈灶性分布但不明显,砂砾体鲜见。肿瘤组织内分布有丰富的结缔组织胶原纤维带,局部密集(图3)。其生物学行为具有侵袭性,术后易复发,偶有脑脊液播散,病理分级为WHO II级。

(天津市环湖医院病理科阎晓玲供稿)