

抗 N-甲基-D-天冬氨酸受体脑炎三例临床分析

苏慧 王蓉飞 于生元

【摘要】 **目的** 探讨抗 N-甲基-D-天冬氨酸受体(NMDAR)脑炎的临床表现、诊断、治疗及预后,以期引起临床医师的重视。**方法与结果** 回顾分析 3 例抗 NMDAR 脑炎患者的诊断与治疗经过,结合临床表现、实验室检查、影像学、脑电图及对治疗的反应,并复习相关文献。3 例患者中 2 例为青年男性、1 例为老年女性;均有精神行为异常,2 例青年男性患者表现为精神亢奋、1 例老年女性患者表现为木僵状态;2 例伴癫痫发作;1 例呼吸机辅助通气。腰椎穿刺脑脊液压力正常,白细胞计数升高,1 例蛋白定量升高。血清和脑脊液抗 NMDAR 阳性。头部 MRI 未见明显异常。脑电图呈现异常。2 例青年男性患者予抗病毒、激素和静脉注射免疫球蛋白治疗,1 例病情好转但遗留精神行为异常,1 年后随访,因家属照料疏忽而意外死亡,1 例病情无变化;1 例老年女性患者仅予抗病毒治疗,遗留轻度记忆和人格变化。**结论** 抗 NMDAR 脑炎是一种新型自身免疫性脑炎,临床表现多样,无特异性,主要为发热、记忆障碍、癫痫发作、意识障碍、自主神经系统功能紊乱,伴或不伴畸胎瘤,对免疫治疗有效。病程与预后存在一定的相关性。

【关键词】 受体, N-甲基-D-天冬氨酸; 脑炎

Anti-N-methyl-D-aspartate receptor encephalitis: analysis of three cases

SU Hui, WANG Rong-fei, YU Sheng-yuan

Department of Neurology, Chinese PLA General Hospital, Beijing 100853, China

Corresponding author: YU Sheng-yuan (Email: yusy1963@126.com)

【Abstract】 **Objective** To study clinical features, diagnosis, therapy response and prognosis of anti-N-methyl-D-aspartate receptor (anti-NMDAR) encephalitis. **Methods** Three cases with anti-NMDAR encephalitis were reported. The clinical features, laboratory examinations, imaging, EEG and therapy response of 3 cases were retrospectively analyzed, and also related literatures were reviewed. **Results** Two patients were young male and one patient was old female. Main symptoms included psychiatric symptoms in 3 cases (mania in 2 male patients and stupor in the female patient), epilepsy in 2 cases and respiratory failure in one case. The results of MRI examination revealed normal, while EEG examination showed abnormal in all cases. No tumor was detected in any of these patients. Lumbar puncture revealed normal cerebrospinal fluid (CSF) pressure (3 cases), elevated white blood cell (WBC, 3 cases) and protein quantification (one case). All cases were confirmed to have the disease by detection of anti-NMDAR antibodies in serum and CSF. One male patient got better after receiving immunotherapy with methylprednisolone and intravenous immunoglobulin (IVIg), but psychiatric symptoms were left over. Another male patient had no response to the above treatment. But the female patient was improved without immunotherapy. All 3 cases were followed up for one year after being discharged. One male patient died by accident because of mental disorders. Another male patient showed no sign of relief. The female patient got mild personality and memory change. **Conclusions** Anti-NMDAR encephalitis is a new type of autoimmune encephalitis. It is characterized by fever, memory deficits, seizures, disturbance of consciousness, and autonomic dysfunction in males and females of all ages. This type of encephalitis is often associated with teratoma, and has a good response to immunotherapy. There is a certain correlation between progression and prognosis.

【Key words】 Receptors, N-methyl-D-aspartate; Encephalitis

doi:10.3969/j.issn.1672-6731.2015.07.013

作者单位:100853 北京,解放军总医院神经内科

通讯作者:于生元(Email:yusy1963@126.com)

抗 N-甲基-D-天冬氨酸受体(NMDAR)脑炎是一种自身免疫性脑炎,由 Dalmau 等^[1]于 2007 年首次提出,临床主要表现为严重的精神症状、行为异常、急性记忆力减退、癫痫发作、运动障碍、通气不足和自主神经系统功能紊乱。任何年龄段均可发病,儿童和女性为主要受累人群,伴或不伴畸胎瘤,临床症状较重,早期诊断、及时治疗,预后相对较好。自 2010 年首都医科大学附属北京友谊医院报告国内首例抗 NMDAR 脑炎病例以来^[2],逐渐对该病有了进一步的认识和了解,相关个案报道也相继出现^[3],多见于女性和儿童,男性和老年女性少见。2012 年 5 月-2013 年 8 月解放军总医院诊断与治疗 3 例抗 NMDAR 脑炎患者,2 例为男性、1 例为老年女性,笔者拟结合文献从该病临床表现、辅助检查、治疗原则和预后等方面进行分析。

例 1 男性,23 岁。主因精神行为异常 2 个月,于 2013 年 2 月 24 日入院。患者入院前 3 周上呼吸道感染后出现言语混乱、精神异常,表现为重复性言语,呈发作性,精神亢奋,睡眠少,持续不缓解,2 d 后当地医院头部 CT 和 MRI 检查未见明显异常,诊断“脑炎”。予抗病毒治疗(具体方案不详)无效,又出现意识不清、高热(体温最高时达 38.3 ℃),遂至我院就诊。患者自发病以来,睡眠少、大小便失禁、体重无变化。入院时呈镇静状态。头部 MRI 检查未见明显异常。病程中出现通气不足,予气管插管呼吸机辅助通气。腰椎穿刺脑脊液压力 110 mm H₂O (1 mm H₂O = 9.81 × 10⁻³ kPa, 80 ~ 180 mm H₂O),白细胞计数为 10 × 10⁶/L [(0 ~ 4) × 10⁶/L],蛋白定量为 0.21 g/L (0.15 ~ 0.40 g/L)、葡萄糖 3.65 mmol/L (2.80 ~ 4.48 mmol/L)、氯化物 126.60 mmol/L (119 ~ 127 mmol/L), IgA 3.10 mg/L (0 ~ 5 mg/L)、IgG 17.90 mg/L (0 ~ 34 mg/L)、IgM 0.35 mg/L (0 ~ 1.30 mg/L),脑脊液细菌、真菌和抗酸杆菌涂片均无异常。血清和脑脊液病毒全项阴性。血清 NMDAR 抗体弱阳性、脑脊液阳性。血清肿瘤学筛查阴性。脑电图显示背景节律以 δ 节律为主,混有部分 θ 节律和少量 α 节律;枕区 α 节律明显不对称;额颞区中波幅 β 节律明显增加(图 1)。临床考虑抗 NMDAR 脑炎,予以甲泼尼龙冲击治疗(1000 mg/d 静脉滴注,治疗 3 d 后,每 3 天剂量减半,逐渐调整为泼尼松 60 mg/d 口服,共治疗 40 d)和静脉注射免疫球蛋白(IVIg, 25 g/d 静脉滴注 × 5 d),病情明显好转,出院时神志清楚,言语清晰,肢体活动可,但遗留精神行为异常,生活自

理能力较差。出院前复查脑脊液压力 130 mm H₂O,白细胞计数 5 × 10⁶/L,蛋白定量 0.21 g/L、葡萄糖 3.24 mmol/L、氯化物 126.60 mmol/L,脑脊液细菌、真菌和抗酸杆菌涂片均未见异常。出院后定期随访,1 年后家属电话告知,患者于某次吃饭时不慎误吸,窒息死亡。

例 2 男性,22 岁。主因精神行为异常 8 个月,间断肢体抽搐、发热 4 月余,于 2012 年 5 月 7 日入院。患者入院前 8 个月无明显诱因出现言语混乱,当地医院诊断“精神分裂症”,予奥氮平和氟哌啶醇对症治疗(具体剂量不详),约 1 周后出现高热(体温最高达 40 ℃)、意识障碍。腰椎穿刺脑脊液检查压力 160 mm H₂O,白细胞计数 60 × 10⁶/L,蛋白定量 0.32 g/L、葡萄糖 3.40 mmol/L、氯化物 120 mmol/L,脑脊液细菌、真菌和抗酸杆菌涂片均无异常。血清肿瘤学筛查阴性。头部 MRI 检查未见异常。脑电图呈界限性脑电图。诊断“病毒性脑炎”,予利巴韦林(具体剂量不详)联合更昔洛韦(250 mg, 1 次/12 h)静脉滴注抗病毒治疗,治疗 2 周后,遗留精神亢奋。4 个月前反复出现意识不清、肢体抽搐,多次至当地医院就诊,经对症处理后抽搐发作停止,但遗留认知功能障碍、肢体活动障碍和大小便障碍,呈去皮质状态,至我院就诊。患者自发病以来,睡眠少、大小便失禁、体重下降约 5 kg。入院时呈去皮质状态,肢体肌容积减少。复查脑脊液压力 130 mm H₂O,白细胞计数 18 × 10⁶/L,蛋白定量 0.59 g/L、葡萄糖为 4.20 mmol/L、氯化物 132 mmol/L, IgA 7.40 mg/L、IgG 101 mg/L、IgM 0.50 mg/L,脑脊液细菌、真菌和抗酸杆菌涂片均无异常。血清和脑脊液病毒全项呈阴性。血清 NMDAR 抗体阳性、脑脊液弱阳性。头部 MRI 增强扫描未见明显异常。脑电图显示全脑持续弥漫性慢波,双侧后颞区和枕区偶见高波幅棘-慢复合波(图 2)。临床考虑抗 NMDAR 脑炎,予甲泼尼龙(500 mg/d)静脉滴注,每 3 天剂量减半,减至 60 mg/d 时改为泼尼松(60 mg/d)口服,症状改善不明显,遂出院。出院后定期随访,病情无明显变化。

例 3 女性,64 岁。主因突发性言语混乱 1 周、睡眠增多 4 d,于 2013 年 7 月 6 日入院。患者入院前 1 周出现言语混乱,无头痛、头晕,无发热、肢体抽搐等,至当地医院就诊,实验室检查轻度低钾、低钠,头部 MRI 增强扫描未见明显异常,纠正电解质紊乱,症状无明显改善。4 d 后出现睡眠增多、肢体僵硬、自主活动明显减少、发热(37.8 ℃),遂至我院就




图1 脑电图显示,背景节律以 δ 节律为主,混有部分 θ 节律和少量 α 节律;枕区 α 节律明显不对称;额颞区中波幅 β 节律明显增加

Figure 1 EEG findings. δ rhythm was predominant on the background which was mingled with some θ rhythm and few α rhythm. Medium-voltage β rhythm increased significantly in temporal and frontal lobes. α rhythm were obviously asymmetric in occipital lobes.

诊。患者自发病以来,睡眠障碍、小便失禁、体重无明显变化。入院时呈缄默状态,四肢肌张力增高,无自主活动,腱反射未引出,病理征阴性,颈项强直。腰椎穿刺脑脊液压力 128 mm H₂O,白细胞计数 $6 \times 10^6/L$,蛋白定量 0.36 g/L、葡萄糖 3.23 mmol/L、氯化物 121.20 mmol/L。血清和脑脊液病毒全项阴性。血清和脑脊液 NMDAR 抗体均呈弱阳性。腹部和妇科 B 超未见肿瘤性病变。脑电图显示广泛性慢波。临床考虑抗 NMDAR 脑炎,拟静脉注射免疫球蛋白,因家庭经济条件较差,仅予阿昔洛韦(200 mg, 1 次/8 h)静脉滴注抗病毒治疗,治疗 1 周后,病情无明显改善,家属放弃治疗。随访得知,患者回当地医院继续治疗 2 周(具体方案不详),逐渐神志清楚,言语清晰,肢体活动可,生活基本能够自理,但遗留轻度近记忆障碍,性格易急躁。定期随访,病情仍逐步改善中。

讨 论

抗 NMDAR 脑炎属自身免疫性脑炎,发病机制不详,由免疫介导致病。近年来,国外文献报道其与单纯疱疹病毒性脑炎(HSE)、多发性硬化(MS)在疾病发生与发展过程中有一定相关性^[4-6],国内仅见儿童继发于单纯疱疹病毒性脑炎的报道^[7]。目前尚

无明确的临床诊断标准。病程大致分为 5 个阶段,包括前驱感染期、精神症状期、无反应期、运动功能亢进期、逐渐恢复期,但每一阶段并无严格界限。约 70% 患者有前驱期,临床主要表现为头痛、发热、恶心、呕吐、腹泻或上呼吸道感染,亦有以运动诱发单侧肢体无力为首发表现者^[8],症状持续数天,一般不超过 3 周^[9-10]。随后出现精神行为异常、人格改变等,持续 10~20 天后出现对外界反应降低、运动障碍、自主神经系统功能紊乱等^[11-13],严重时可出现反复癫痫发作、意识障碍、通气障碍,需呼吸机辅助通气,多数患者整个病程持续 3~4 个月^[9,14]。尽管抗 NMDAR 脑炎患者临床症状较重,但有 50%~70% 的患者头部 MRI 正常,其余则表现为 T₂WI 或 FLAIR 成像高信号,病灶多位于海马、大脑皮质、岛叶、基底节、脑干、小脑,偶见脊髓,增强扫描可见病灶及相应部位脑(脊)膜强化。对于 MRI 无异常表现的患者,可选择性进行扩散张量成像(DTI),据脑白质损伤程度判断预后^[9,15]。脑电图通常表现为非特异性慢波,有时伴节律紊乱的脑电活动,也可表现为正常脑电图。有学者认为,异常的 δ 刷是抗 NMDAR 脑炎特征性表现,可于长时程脑电监测时发现^[16-17]。最重要的诊断依据是血清和(或)脑脊液 NMDAR 抗体阳性^[1,9],但 NMDAR 抗体滴度及其持续阳性时间

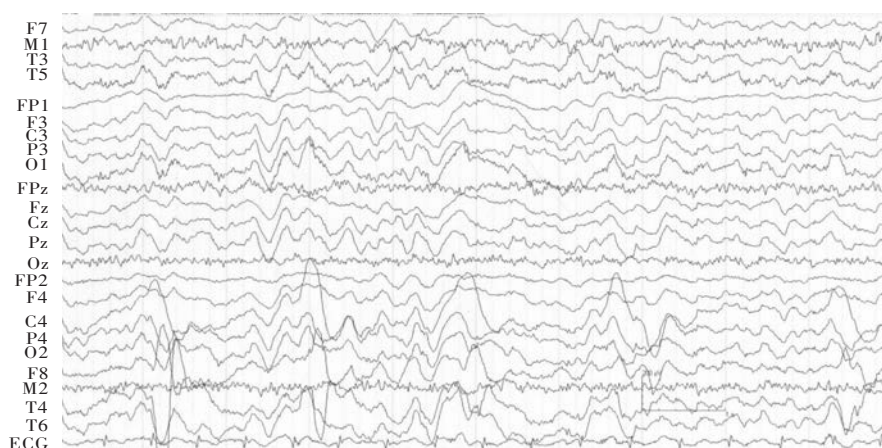


图2 脑电图显示,全脑持续弥漫性慢波,双侧后颞区和枕区偶见高波幅棘-慢复合波

Figure 2 EEG showed continuous diffuse slow waves in each lead, and high-voltage spike-slow waves were occasionally seen in bilateral posterior temporal and occipital lobes.

是否与疾病预后相关,尚存争议^[3,14,18]。

关于抗NMDAR脑炎的治疗,关键是及时开始免疫治疗,若合并畸胎瘤,应及时予以切除。目前,一线免疫治疗方法包括激素冲击治疗、静脉注射免疫球蛋白或血浆置换疗法。对于不合并肿瘤、治疗延迟或对免疫治疗反应较差的患者,可考虑二线治疗药物如利妥昔单抗或环磷酰胺,效果较好^[19-23]。抗NMDAR脑炎复发率为20%~25%^[10,19,24],二线药物可以降低其复发率^[25]。但迄今对免疫治疗药物剂量和持续时间,仍无明确定论。

目前,有文献以抗NMDAR脑炎主要临床特点为依据,对其进行分型^[26]:1型为病程<60天、以昏迷为主的患者;2型为以精神行为异常为主的患者;3型为病程≥60天、以精神紧张为主的患者。本组3例患者均临床表现为发热、精神症状、意识不清等,并遗留精神症状,3种类型均有所涉及。与国内文献报道的抗NMDAR脑炎^[27]不同的是,3例患者影像学均无明显异常,肿瘤学筛查均呈阴性。其中1例男性患者经激素冲击治疗和静脉注射免疫球蛋白后,病情改善;1例男性患者因病情反复、持续时间较长,且反复合并严重感染,未应用免疫抑制剂,仅予以激素冲击治疗,效果欠佳;1例老年女性患者仅予以阿昔洛韦静脉滴注,病情逐渐好转。是否提示抗NMDAR脑炎与其他类型脑炎一样无需免疫治疗^[28],值得探讨。此外,其中1例男性患者虽经免疫治疗,病情好转,但因家属照料疏忽,进食时不慎误吸致死,提示细心周到的家庭护理同样重要。

尽管目前国内抗NMDAR脑炎的报道日益增

多,但并未引起临床医师对该病的充分认识和重视。临床中对伴或仅有精神症状可疑脑炎的患者,尤其是已明确诊断的单纯疱疹病毒性脑炎患者,无论性别和年龄,在行头部影像学、血清和脑脊液病毒学检查的同时,应尽早完善血清和脑脊液NMDAR抗体等自身免疫性脑炎相关抗体检测,对明确诊断至关重要。约58%的患者伴肿瘤^[9],故对于就诊期间未发现肿瘤的患者,应作好随访工作,建议每2年进行一次肿瘤筛查^[14]。对于遗留执行功能下降的患者,应加强家庭护理,避免悲剧再次发生。目前,尚无抗NMDAR脑炎自发性缓解的报道,因此,应早认识、早发现、早诊断、早治疗,以提高患者生存率和生活质量,减轻家庭和社会负担。

参 考 文 献

- [1] Dalmau J, Tüzün E, Wu HY, Masjuan J, Rossi JE, Voloschin A, Baehring JM, Shimazaki H, Koide R, King D, Mason W, Sansing LH, Dichter MA, Rosenfeld MR, Lynch DR. Paraneoplastic anti-N-methyl-D-aspartate receptor encephalitis associated with ovarian teratoma. *Ann Neurol*, 2007, 61:24-36.
- [2] Xu CL, Zhao WQ, Li JM, Wang JW, Wang SH, Wang DX, Liu MY, Qiao SS, Jin JY, Hao ZP, Ji XJ. Anti-N-methyl-D-aspartate receptor encephalitis: an adolescent with ovarian teratoma. *Zhonghua Shen Jing Ke Za Zhi*, 2010, 43:781-783. [许春伶, 赵伟秦, 李继梅, 王佳伟, 王淑辉, 王得新, 刘美云, 乔衫衫, 靳家玉, 郝增平, 冀晓俊. 抗N-甲基-D-天冬氨酸受体脑炎一例. *中华神经科杂志*, 2010, 43:781-783.]
- [3] Xu YY, Liu Q, Peng B, Cui LY. A 16-year-old woman with fever, epilepsy and diplopia. *Zhongguo Xian Dai Shen Jing Ji Bing Za Zhi*, 2013, 13:544-549. [许玉园, 柳青, 彭斌, 崔丽英. 发热 癫痫发作 复视. *中国现代神经疾病杂志*, 2013, 13:544-549.]
- [4] Leypoldt F, Titulaer MJ, Aguilar E, Walther J, Bönstrup M, Havemeister S, Teegen B, Lütgehetmann M, Rosenkranz M,

- Magnus T, Dalmau J. Herpes simplex virus-1 encephalitis can trigger anti - NMDA receptor encephalitis: case report. *Neurology*, 2013, 81:1637-1639.
- [5] Desena A, Graves D, Warnack W, Greenberg BM. Herpes simplex encephalitis as a potential cause of anti-N-methyl-D-aspartate receptor antibody encephalitis: report of 2 cases. *JAMA Neurol*, 2014, 71:344-346.
- [6] Yamamoto M, Kokubun N, Watanabe Y, Okabe R, Nakamura T, Hirata K. NMDA receptor encephalitis in the course of recurrent CNS demyelinating disorders: a case report. *Rinsho Shinkeigaku*, 2013, 53:345-350.
- [7] Wu Y, Zhang WH, Lü JL, Wang XH, Ren HT, Cui LY, Fang F. Four cases report of anti - N - methyl - D - aspartate receptor encephalitis in herpes simplex encephalitis. *Zhongguo Xun Zheng Er Ke Za Zhi*, 2014, 9:223-226.[伍斌, 张伟华, 吕俊兰, 王晓慧, 任海涛, 崔丽英, 方方. 继发于单纯疱疹病毒性脑炎的抗N-甲基-D-天门冬氨酸受体脑炎4例病例报告. *中国循证儿科杂志*, 2014, 9:223-226.]
- [8] Labate A, Quattrone A, Dalmau J, Gambardella A. Anti - N - methyl-D-aspartate-glutamic-receptor encephalitis presenting as paroxysmal exercise-induced foot weakness. *Mov Disord*, 2013, 28:820-822.
- [9] Dalmau J, Gleichman AJ, Hughes EG, Rossi JE, Peng X, Lai M, Dessain SK, Rosenfeld MR, Balice-Gordon R, Lynch DR. Anti-NMDA receptor encephalitis: case series and analysis of the effects of antibodies. *Lancet Neurol*, 2008, 7:1091-1098.
- [10] Irani SR, Bera K, Waters P, Zuliani L, Maxwell S, Zandi MS, Friese MA, Galea I, Kullmann DM, Beeson D, Lang B, Bien CG, Vincent A. N - methyl - D - aspartate antibody encephalitis: temporal progression of clinical and paraclinical observations in a predominantly non - paraneoplastic disorder of both sexes. *Brain*, 2010, 133(Pt 6):1655-1667.
- [11] Maramattom BV, Jacob A. N - methyl - D - aspartate receptor encephalitis: a new addition to the spectrum of autoimmune encephalitis. *Ann India Acad Neurol*, 2011, 14:153-157.
- [12] Ferioli S, Dalmau J, Kobet CA, Zhai QJ, Broderick JP, Espay AJ. Anti - N - methyl - D - aspartate receptor encephalitis: characteristic behavioral and movement disorder. *Arch Neurol*, 2010, 67:250-251.
- [13] Sharma B, Handa R, Prakash S, Nagpal K, Gupta P. Anti - NMDA receptor encephalitis: a neurological disease in psychiatric disguise. *Asian J Psychiatr*, 2014, 7:92-94.
- [14] Dalmau J, Lancaster E, Martinez-Hernandez E, Rosenfeld MR, Balice - Gordon R. Clinical experience and laboratory investigations in patients with anti - NMDAR encephalitis. *Lancet Neurol*, 2011, 10:63-74.
- [15] Finke C, Kopp UA, Scheel M, Pech LM, Soemmer C, Schlichting J, Leyboldt F, Brandt AU, Wuerfel J, Probst C, Ploner CJ, Prüss H, Paul F. Functional and structural brain changes in anti - N - methyl - D - aspartate receptor encephalitis. *Ann Neurol*, 2013, 74:284-296.
- [16] Schmitt SE, Pargeon K, Frechette ES, Hirsch LJ, Dalmau J, Friedman D. Extreme delta brush: a unique EEG pattern in adults with anti-NMDA receptor encephalitis. *Neurology*, 2012, 79:1094-1100.
- [17] da Silva-Júnior FP, Castro LH, Andrade JQ, Bastos CG, Moreira CH, Valério RM, Jorge CL, Marchiori PE, Nitri R, Garzon E. Serial and prolonged EEG monitoring in anti - N - methyl - D - aspartate receptor encephalitis. *Clin Neurophysiol*, 2014, 125: 1541-1544.
- [18] Liu L, Song ZH, Dai FF, Guo J, Xu CL, Wang RJ, Wang JW. Clinical analysis in 45 patients with anti-N-methyl-D-aspartate receptor encephalitis//Shandong Neurology Conference & Neuroimmunological Congress 2013, Tai'an, 2013. Ji'nan: Shandong Medical Association, 2013: 231.[刘磊, 宋兆慧, 代飞, 郭晶, 许春伶, 王瑞金, 王佳伟. 45例抗NMDA受体脑炎临床分析//山东省2013年神经内科学学术会议暨中国神经免疫大会2013论文汇编, 泰安, 2013. 济南: 山东省医学会, 2013: 231.]
- [19] Florence NR, Davis RL, Lain C, Szperka C, Zhou L, Ahmad S, Campen CJ, Moss H, Peter N, Gleichman AJ, Glaser CA, Lynch DR, Rosenfeld MR, Dalmau J. Anti - N - methyl - D - aspartate receptor (NMDAR) encephalitis in children and adolescents. *Ann Neurol*, 2009, 66:11-18.
- [20] Ishiura H, Matsuda S, Higashihara M, Hasegawa M, Hida A, Hanajima R, Yamamoto T, Shimizu J, Dalmau J, Tsuji S. Response of anti-NMDA receptor encephalitis without tumor to immunotherapy including rituximab. *Neurology*, 2008, 71:1921-1923.
- [21] Ikeguchi R, Shibuya K, Akiyama S, Hino S, Kubo H, Takeda T, Shibata N, Yamamoto K. Rituximab used successfully in the treatment of anti - NMDA receptor encephalitis. *Intern Med*, 2012, 51:1585-1589.
- [22] Turkdogan D, Oregul AC, Zaimoglu S, Ekinci G. Anti-N-methyl-D - aspartate (Anti - NMDA) receptor encephalitis: rapid and sustained clinical improvement with steroid therapy starting in the late phase. *J Child Neurol*, 2014, 29:684-687.
- [23] Frechette ES, Zhou L, Galetta SL, Chen L, Dalmau J. Prolonged follow-up and CSF antibody titers in a patient with anti-NMDA receptor encephalitis. *Neurology*, 2011, 76(Suppl 2):64-66.
- [24] Kayal AK, Das M, Bhowmick S, Synmon B. Relapsing Anti - NMDAR encephalitis after a gap of eight years in a girl from North-East India. *Ann Indian Acad Neurol*, 2014, 17:349-351.
- [25] Titulaer MJ, McCracken L, Gabilondo I, Armangué T, Glaser C, Iizuka T, Honig LS, Benseler SM, Kawachi I, Martinez - Hernandez E, Aguilar E, Gresa-Arribas N, Ryan-Flourance N, Torrents A, Saiz A, Rosenfeld MR, Balice-Gordon R, Graus F, Dalmau J. Treatment and prognostic factors for long - term outcome in patients with anti-NMDA receptor encephalitis: an observational cohort study. *Lancet Neurol*, 2013, 12:157-165.
- [26] DeSena AD, Greenberg BM, Graves D. Three phenotypes of anti-N-methyl-D-aspartate receptor antibody encephalitis in children: prevalence of symptoms and prognosis. *Pediatr Neurol*, 2014, 51: 542-549.
- [27] Zhou GE, An ZP. Anti - N - methyl - D - aspartate receptor encephalitis: three cases report and review of literature. *Zhongguo Xian Dai Shen Jing Ji Bing Za Zhi*, 2014, 14:575-579. [周官恩, 安中平. 抗N-甲基-D-天冬氨酸受体脑炎: 三例报告并文献复习. *中国现代神经疾病杂志*, 2014, 14:575-579.]
- [28] Szots M, Marton A, Kover F, Kiss T, Berki T, Nagy F, Illes Z. Natural course of LGI1 encephalitis: 3-5 years of follow - up without immunotherapy. *J Neurol Sci*, 2014, 343(1/2):198-202.

(收稿日期: 2015-05-22)

本期广告目次

- 泰嘉(深圳信立泰药业股份有限公司) 封二
- 诺百益(济南利民制药有限责任公司) 封三
- 申捷(齐鲁制药有限公司) 封四